

Optical coherence tomography for the diagnosis of malignant skin tumors: a meta-analysis

Yi-Quan Xiong
Yun Mo
Yu-Qi Wen
Ming-Ji Cheng
Shu-Ting Huo
Xue-Jiao Chen
Qing Chen

Optical coherence tomography for the diagnosis of malignant skin tumors: a meta-analysis

Yi-Quan Xiong,[†] Yun Mo,[†] Yu-Qi Wen, Ming-Ji Cheng, Shu-Ting Huo, Xue-Jiao Chen, and Qing Chen*

Southern Medical University, School of Public Health, Guangdong Provincial Key Laboratory of Tropical Disease Research, Department of Epidemiology, Guangzhou, China

Abstract. Optical coherence tomography (OCT) is an emergent imaging tool used for noninvasive diagnosis of skin diseases. The present meta-analysis was carried out to assess the accuracy of OCT for the diagnosis of skin cancer. We conducted a systematic literature search through EMBASE, Medline, PubMed, the Cochrane Library, and Web of Science database for relevant articles published up to June 6, 2017. The quality of the included studies was assessed using the QUADAS-2 tool and the Oxford Levels of Evidence Scale. Statistical analyses were conducted using the software Meta-Disc version 1.4 and STATA version 12.0. A total of 14 studies involving more than 813 patients with a total of 1958 lesions were included in our analyses. The pooled sensitivity and specificity of OCT for skin cancer diagnoses were 91.8% and 86.7%, respectively. Subgroup analysis showed that the pooled sensitivities of OCT for detecting basal cell carcinoma (BCC), squamous cell carcinoma (SCC), actinic keratosis, and malignant melanoma were 92.4%, 92.3%, 73.8%, and 81.0%, respectively. The pooled specificities were 86.9%, 99.5%, 91.5%, and 93.8%, respectively. OCT appears to be useful for the detection of BCC and SCC. It is a valuable diagnostic method when screening for early skin cancers. © 2018 Society of Photo-Optical Instrumentation Engineers (SPIE) [DOI: [10.1117/1.JBO.23.2.020902](https://doi.org/10.1117/1.JBO.23.2.020902)]

Keywords: optical coherence tomography; skin cancer; basal cell carcinoma; squamous cell carcinoma; actinic keratosis; malignant melanoma.

Paper 170502VR received Aug. 6, 2017; accepted for publication Jan. 29, 2018; published online Feb. 22, 2018.

1 Introduction

Alarming increases in the incidence and prevalence of malignant skin tumors have occurred in recent decades, especially for malignant melanoma (MM), basal cell carcinoma (BCC), and squamous cell carcinoma (SCC).¹⁻⁵ Nonmelanoma skin cancers (NMSC), including Bowen's disease, actinic keratosis (AK), BCC, and SCC, are the most prevalent malignancies affecting light-skinned individuals worldwide and represent almost 95% of all cutaneous cancer diagnoses.^{6,7} The World Health Organization reported an increase of more than 2 to 3 million new cases of NMSC per year,⁸ of which about 80% are BCCs.⁹ Meanwhile, MM is also increasing in frequency both in the UK and Europe.³ MM accounts for 2% of skin cancers and is responsible for nearly 1% of deaths caused by oncological etiologies.¹⁰ Both NMSC and MM have excellent prognosis when they are diagnosed and treated early.¹¹ If melanoma is treated while *in situ* or stage 1, the overall 5-year survival rate is over 90%, but for metastatic disease at stage 4, the rate drops rapidly to 10% to 15%.¹¹ Thus, diagnosis at an early stage is crucial for improving survival rates and overall prognosis,¹²⁻¹⁴ and it is important that dermatologists not only provide preventative counseling but also be astute in the early diagnosis and treatment of any suspected malignancies.¹⁵

Several new methods offer improved diagnoses of skin lesions.¹⁶ In particular, the development of optospectral technologies for imaging of living tissues is reshaping the dermatological practice. This technique offers *in vivo/ex vivo*, noninvasive, painless, real-time visualization of skin structures and physiological parameters, at high resolution and without interfering with the morphology and the functions of the examined integument.¹⁷⁻¹⁹

Optical coherence tomography (OCT) was first used medically in 1988 in ophthalmology by Fercher et al.²⁰ This method is based on the physical principle of low-coherence interferometry and uses infrared light²¹ to measure the scattering properties of tissues (echo time delay and the intensity of backscattered or backreflected light).²²⁻²⁴ It provides a real-time, cross-sectional as well as *en-face* sectional images of the subsurface microstructure of tissues with micrometer resolution, enabling visualization of skin morphology (epidermis, dermis, dermoepidermal junction, nodular and fibrous structures, cellular elements, hair follicle units, blood vessels, and sweat glands) and investigation of the altered skin architecture present in superficial skin lesions.^{13,19,25,26} High-definition OCT (HD-OCT) is a technique based on the principal of conventional OCT using a combination of parallel time-domain interferometry and adaptive optics.²⁷ Conventional OCT techniques, such as VivoSight OCT, polarized sensitivity OCT (PS-OCT), Skintell HD-OCT, or full-field OCT (FF-OCT), offer two-dimensional (brightness-scan mode) and three-dimensional (3-D) (c-scan mode) reconstruction of the images with acquisition speeds reported to be up to several volumes per second, as well as noise removal.²⁸

In recent years, it has been demonstrated that melanocytic lesions such as AK, SCC, and BCC have distinctive features revealed using OCT that can differentiate them from noncancerous skin lesions.²⁹⁻³² However, the reported diagnostic accuracy of OCT is inconsistent. To formulate a comprehensive basis for use of OCT, we performed a meta-analysis of the literature to assess OCT for differentiating skin tumors from normal skin.

2 Methods

This meta-analysis was conducted according to the published standards for reviews of diagnostic accuracy and performed

*Address all correspondence to: Qing Chen, E-mail: qch.2009@163.com

[†]Authors contributed equally to this work.

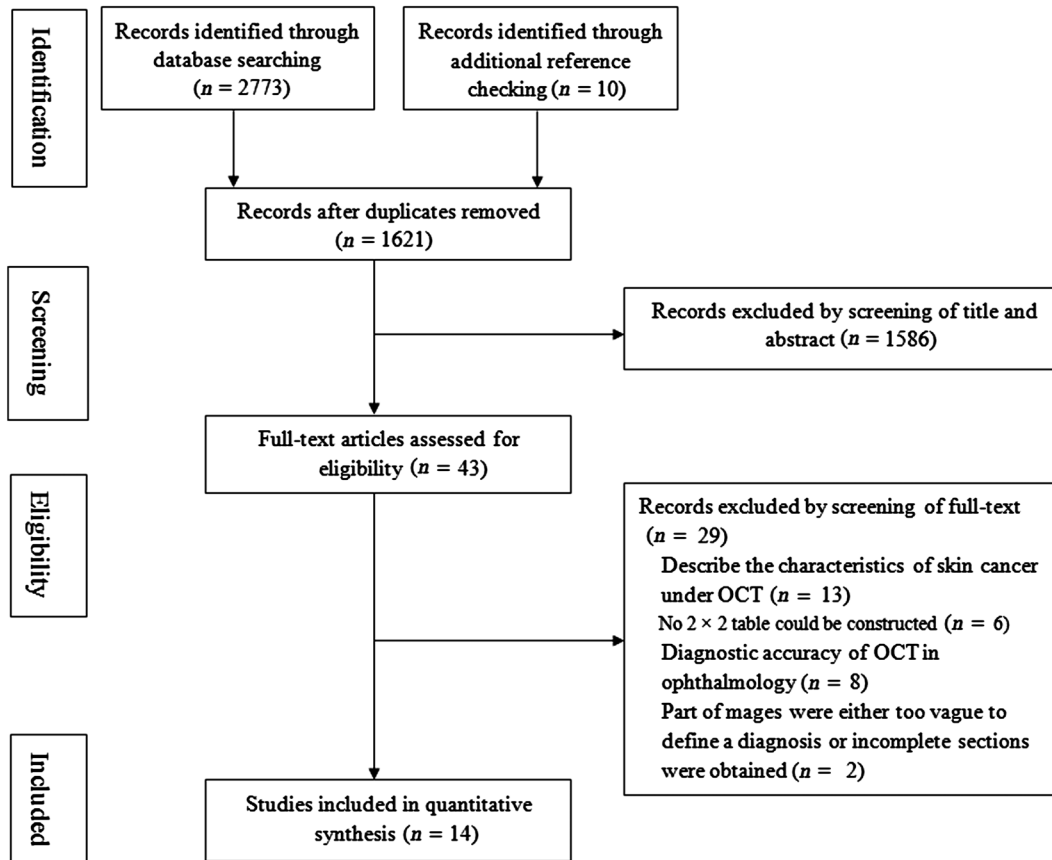


Fig. 1 Flow diagram of the studies identified in the meta-analysis. OCT, optical coherence tomography.

in accordance with the Preferred Reporting Items for Systematic Reviews and Meta-Analyses guidelines.³³

2.1 Literature Search

Electronic searches were conducted of EMBASE, Medline, PubMed, the Cochrane Library, and the Web of Science databases from the earliest date available until June 6, 2017. We used the following key words, separately and in combination: “skin,” “tumor,” “cancer,” “neoplasm,” “carcinoma,” “melanoma,” “basal cell carcinoma,” “BCC,” “squamous cell carcinoma,” “SCC,” “optical coherence tomography,” and “OCT.” No language restriction was applied to the searches, but the search was restricted to studies on humans. Forward citation searching of the reference lists of the original studies and review articles was also conducted.

2.2 Eligibility Criteria

Studies were screened for eligibility using the following criteria: (i) evaluation by diagnostic clinical trials of the accuracy of OCT for the diagnosis of skin cancer in patients, (ii) retrospective or prospective study design, (iii) results reported with sufficient data to construct a diagnostic 2×2 contingency table, including true-positive, false-positive, true-negative, and false-negative data, and (iv) all diagnoses were confirmed by the histology seen in a biopsy sample. Comment papers, small case series, case reports, reviews, or guideline articles were excluded. When more than one article reported the same study, the publication with more information was selected.

2.3 Data Selection and Extraction

Citations were merged in EndNote (version X7) to facilitate management. Two authors independently evaluated all retrieved articles by title and abstract according to the previous inclusion criteria in a nonblinded, standardized manner. After full-text screening, articles that fulfilled the inclusion criteria were selected for the final analysis. Data were extracted from each eligible study by two authors independently and a consensus was reached on all items. Relevant data included: (i) first author, year of publication, country of origin, study design (prospective or retrospective), number of centers; (ii) type of OCT system, (iii) *in vivo* or *ex vivo* examination; (iv) type of skin cancer; (v) number of investigators and their experience, OCT analysis (blinded or others); (vi) number of enrolled patients and specimens, baseline patient characteristics (age distribution and sex ratio); and (vii) accuracy of OCT (sensitivity and specificity) with reference to histopathology.

2.4 Quality Assessment

The quality of the included studies and the risk of bias were assessed according to the Oxford Centre for Evidence-based Medicine-Levels of Evidence (March 2009)³⁴ and the Quality Assessment of Diagnostic Accuracy Studies-2 (QUADAS-2)³⁵ tools by two authors independently. QUADAS-2 consists of four key domains regarding patient selection, index test, reference standard, and flow of patients (through the study and timing of the index tests). Risk of bias was judged as “low,” “high,” and “unclear.”

Table 1 Basic characteristics of selected studies.

Author	Year	Country	Design	Center (n)	Type of OCT	Type of cancer	Investigators	Experienced	Patients (n)	Age (mean or median)	Male (%)	Lesions	Levels of evidence
Gambichler et al. ¹²	2015	Germany	Pro	Three	Skintell HD-OCT	MM	One	Exp	64	NA	NA	93	1a
Hussain et al. ¹	2016	Denmark	Pro	One	VivoSight OCT	BCC	NA	NA	58	65.9 (41 to 88)	37.5	58	1b
Mogensen et al. ¹³	2009	Denmark	Retro	One	OCT and PS-OCT	NMSC	Two	Exp	104	69.3 (37 to 90)	43.0	220	1b
Markowitz et al. ³⁹	2015	USA	Pro	Three	VivoSight OCT	BCC	NA	NA	NA	NA	NA	115	1a
Maier et al. ⁴⁰	2014	Germany	Pro	One	Skintell HD-OCT	BCC	One	Exp	20	NA (53 to 90)	55.0	80	1b
Durkin et al. ⁴¹	2014	USA	Retro	One	FF-OCT	SCC, BCC	One	NA	11	NA	NA	18	1b
Ulrich et al. ⁴²	2015	Germany	Pro	Six	VivoSight OCT	BCC	NA	Exp	155	70 (33 to 90)	NA	235	1a
Wahrlich et al. ⁴³	2015	Germany	Pro	One	VivoSight OCT	BCC	One	Exp	50	62.8	46.0	50	1b
Boone et al. ⁴⁵	2016	Denmark	Retro	One	Skintell HD-OCT	AK, SCC	NA	NA	108	66.3 (39 to 92)	47.8	108	1b
Marvdashti et al. ⁴⁷	2016	USA	Retro	One	PS-OCT	BCC	One	Exp	42	NA	NA	520	1b
Olsen et al. ⁴⁶	2016	Denmark	Pro	One	VivoSight OCT	AK, BCC	Five	Exp	NA	69.4	54.9	142	1b
Boone et al. ⁴⁸	2016	Denmark	Retro	One	Skintell HD-OCT	MM	NA	NA	45	51 (20 to 70)	44.4	45	1b
Marneffe et al. ⁴⁴	2016	Belgium	Retro	One	Skintell HD-OCT	AK, SCC	Three	Exp	71	66.9 (35 to 91)	50.7	106	1b
Cheng et al. ⁴⁹	2016	Australia	Pro	One	OCT	BCC	Three	Exp	103	66 (31 to 88)	61.2	168	1b

Note: OCT, optical coherence tomography; HD-OCT, high-definition OCT; PS-OCT, polarized sensitivity OCT; MM, malignant melanoma; BCC, basal cell carcinoma; SCC, squamous cell carcinoma; AK, actinic keratosis; NMSC, nonmelanoma skin cancer; AHM, amelanotic/hypomelanotic melanoma; NA, no data available; Pro, prospective; Retro, retrospective; and Exp, experienced.

2.5 Statistical Analysis

Sensitivity, specificity, positive likelihood ratio (PLR), and negative likelihood ratio (NLR) were meta-analyzed. Between-studies heterogeneity was estimated by I^2 statistics; significant heterogeneity was defined as $I^2 > 50\%$. Pooled results and their corresponding 95% confidence intervals (CIs) were calculated with a fixed-effects model (Mantel and Haenszel method) when heterogeneity was not significant ($I^2 < 50\%$); otherwise, a random-effects model (DerSimonian and Laird method) was applied. Forest plots were constructed for visual display of pooled results if necessary. A weighted symmetric summary receiver operating characteristic (sROC) curve was drawn, and the area under the curve (AUC) was calculated.³⁶ Threshold analysis was performed using the Spearman's coefficient (>0.5 with $p < 0.05$).³⁷ Meta-regression was also performed to explore the potential heterogeneity among studies. Statistical analyses were conducted using Meta-Disc software (version 1.4; Unit of Clinical Biostatistics, Ramon y Cajal Hospital, Madrid, Spain).³⁸ Publication bias was assessed using STATA (version 12.0; Stata Corp; College Station, Texas), and the Midas command was used for all statistical analyses.

3 Results

3.1 Description of the Included Studies

The initial search yielded 2773 references, of which 1621 potentially relevant studies were unique. Fourteen studies,^{1,12,13,39-49} including eight prospective and six retrospective studies, that involved more than 813 patients and 1958 lesions were included in the final analysis. The selection process for the studies is

shown in Fig. 1. The main characteristics of the 14 studies^{1,12,13,39-49} are summarized in Table 1. All of the studies were conducted in the USA, Germany, Belgium, Australia, and Denmark, and three were multicenter studies.^{12,39,42} Five studies used VivoSight OCT,^{1,39,42,43,46} five used Skintell HD-OCT,^{12,40,44,45,48} two used PS-OCT,^{13,47} and the remaining one used FF-OCT.⁴¹ All included studies covered most types of skin cancer, including MM, AK, BCC, and SCC. Twelve studies^{1,12,13,39-42,44-48} reported the diagnostic performance of OCT in differentiating cancerous from noncancerous skin, and some studies validated the distinction of BCC,^{1,39-43,46,47,49,50} SCC,^{41,44,48} AK,^{44,46,48} or MM^{12,45} from other cancerous or non-cancerous lesions, respectively. Three studies^{43,47,48} used a newly developed scoring systems [the "Berlin score" (BS)] or algorithms as assisting tools in detection. Nine studies^{12,13,40,42-44,46,47,49} noted the experience of the observers who examined the outcomes of OCT images.

3.2 Quality Assessment

Two scales were used for assessing the study quality. The results assessed using the Oxford Levels of Evidence Scale are shown in Table 1, and the results assessed using QUADAS-2 are shown in Table 2. Most of the studies included in our analysis were of high quality. One study¹³ had a high risk of bias in patient selection because normal adjacent skin areas were selected to use as the control sites. Four studies, in which some patients were excluded from the final analysis because of lack of information^{1,42} or absence of optimal quality OCT images,^{13,47} were classified as having a high risk of bias in flow and timing. And in one

Table 2 QUADAS-2 risk of bias assessment.

Study	Risk of bias				Applicability concerns		
	Patient selection	Index test	Reference standard	Flow and timing	Patient selection	Index test	Reference standard
Gambichler et al. ¹²	Low	Low	Low	Low	Low	Low	Low
Hussain et al. ¹	Low	Low	Low	High	Low	Low	Low
Mogensen et al. ¹³	High	Low	Low	High	Low	Low	Low
Markowitz et al. ³⁹	Low	Low	Unclear	Low	Low	Low	Low
Maier et al. ⁴⁰	Low	Low	Low	Low	Unclear	Low	Low
Durkin et al. ⁴¹	Low	Low	Low	Low	Low	Low	Low
Ulrich et al. ⁴²	Low	Low	Low	High	Low	Low	Low
Wahrlich et al. ⁴³	Low	Low	Low	Low	Low	Low	Low
Boone et al. ⁴⁵	Low	Unclear	Low	Low	Low	Low	Low
Marvdashti et al. ⁴⁷	Low	Unclear	Low	High	Low	Low	Low
Olsen et al. ⁴⁶	Low	Low	Low	Low	Low	Low	Low
Boone et al. ⁴⁸	Low	Unclear	Low	Low	Low	Low	Low
Marneffe et al. ⁴⁴	Low	Low	Low	High	Low	Low	Low
Cheng et al. ⁴⁹	Low	Low	Low	Low	Low	Low	Low

Note: Low, low risk; High, high risk; and Unclear, unclear risk.

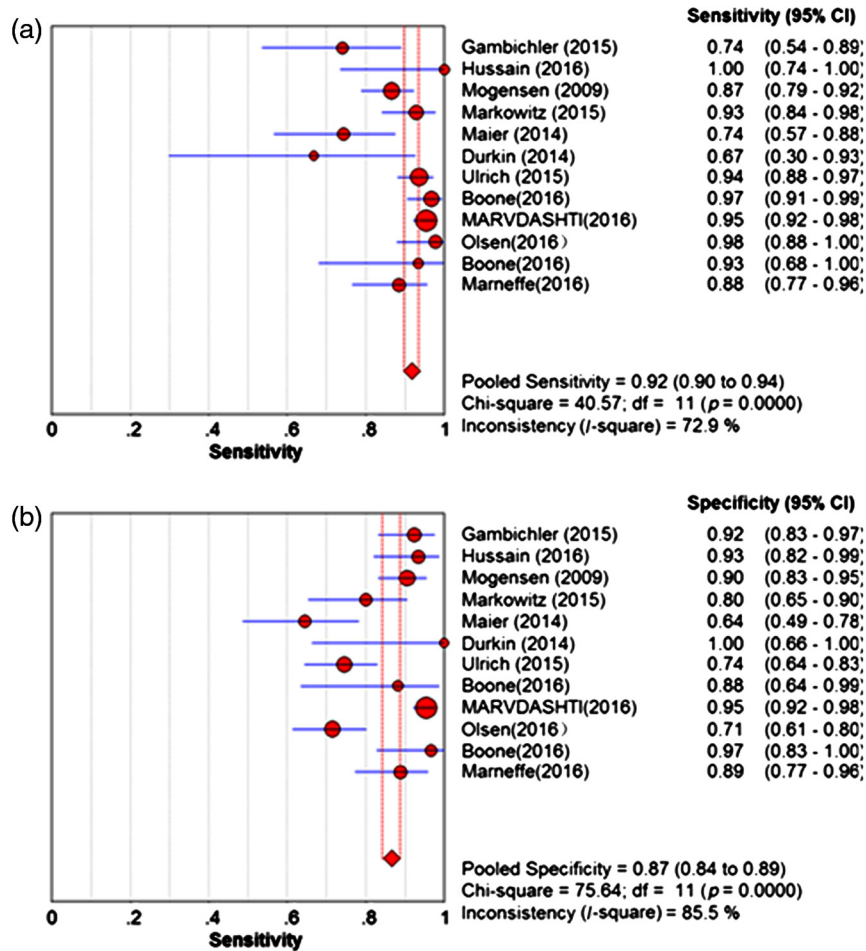


Fig. 2 Forest plot of the (a) pooled sensitivity and (b) specificity of OCT for detection of malignant skin tumors.

study,⁴⁴ the control patients did not have the same reference standards as the cases, suggesting a high risk of selection bias.

3.3 Diagnostic Accuracy of OCT for Skin Cancer

Twelve studies,^{1,12,13,39-42,44-48} including a total of 1740 lesions, reported the diagnostic accuracy of OCT for distinguishing cancerous from noncancerous features at the per-lesion level. The sensitivity ranged from 66.7% to 100.0% and specificity ranged from 64.4% to 100.0%. The corresponding pooled sensitivity and specificity were 91.8% (95% CI: 0.90 to 0.94, $I^2 = 72.9%$) and 86.7% (95% CI: 0.84 to 0.89, $I^2 = 85.5%$), respectively (Fig. 2). The pooled PLR and NLR were 6.94 (95% CI: 4.21 to 11.47, $I^2 = 86.3%$) and 0.12 (95% CI: 0.07 to 0.20, $I^2 = 79.1%$), respectively. The AUC for sROC was 0.95 (Fig. 3). The distribution of scatter points in the sROC was not in a shoulder-like form and the Spearman's coefficient was 0.14 ($p = 0.67$), suggesting that there was no threshold effect.

3.4 Diagnostic Accuracy of OCT for BCC

Nine studies,^{1,39-43,46,47,49} covering a total of 1386 lesions, reported the diagnoses of BCC by OCT. The pooled sensitivity was 92.4% (95% CI: 0.90 to 0.94, $I^2 = 71.7%$) and specificity was 86.9% (95% CI: 0.84 to 0.89, $I^2 = 89.4%$); whereas the pooled PLR and NLR were 6.07 (95% CI: 3.27 to 11.26, $I^2 = 88.9%$) and 0.12 (95% CI: 0.07 to 0.23, $I^2 = 80.3%$), respectively. The AUC for sROC was 0.95 (Table 3).

3.5 Diagnostic Accuracy of OCT for SCC

Three studies,^{41,44,48} including the diagnoses of SCC, achieved a pooled sensitivity of 92.3% (95% CI: 0.79 to 0.98, $I^2 = 71.2%$) and a high specificity of 99.5% (95% CI: 0.97 to 1.00, $I^2 = 0.0%$); then the pooled PLR and NLR were

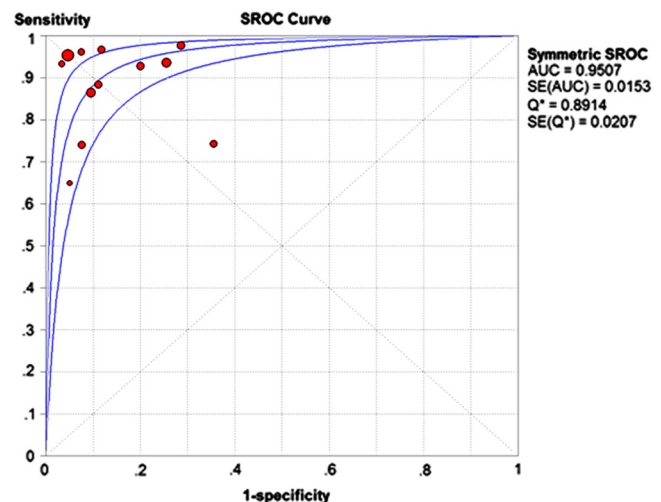


Fig. 3 The sROC with 95% CI of OCT for detection of malignant skin tumors. AUC, area under the curve.

Table 3 Subgroup analysis of some important indices (with 95% CIs).

Kind of cancer	Number of studies (lesions)	Heterogeneity (I^2) (%)		Specificity (95% CI, %)		Heterogeneity (I^2) (%)		Positive LR (95% CI)		Heterogeneity (I^2) (%)		Negative LR (95% CI)		Heterogeneity (I^2) (%)		AUC	
		Sensitivity (95% CI, %)															
BCC	9 (1386)	92.4% (90.3 to 94.3)	71.7	86.9% (84.1 to 89.4)	89.4	6.07 (3.27 to 11.3)	88.9	0.12 (0.07 to 0.23)	80.3	0.95							
SCC	3 (232)	92.3% (79.1 to 98.4)	71.2	99.5% (97.1 to 100.0)	0.0	68.01 (17.0 to 272)	0.0	0.11 (0.01 to 1.20)	82.0	1.00							
AK	3 (356)	73.8% (66.5 to 80.3)	96.7	91.5% (86.5 to 95.1)	0.0	7.67 (3.94 to 14.9)	40.4	0.17 (0.02 to 1.34)	96.4	0.97							
MM	2 (138)	81.0% (65.9 to 91.4)	62.3	93.8% (86.9 to 97.7)	0.0	11.82 (5.16 to 27.0)	3.4	0.18 (0.05 to 0.71)	54.0	0.5							
<i>In/ex vivo</i>																	
<i>In vivo</i>	9 (1122)	91.6% (89.0 to 93.8)	61.7	84.1% (80.8 to 87.1)	76.4	6.35 (4.30 to 9.39)	68.6	0.11 (0.07 to 0.17)	51.4	0.95							
<i>Ex vivo</i>	3 (618)	92.1% (88.5 to 94.9)	89.6	91.1% (87.4 to 94.0)	93.9	7.75 (0.80 to 75.2)	96.6	0.19 (0.04 to 1.00)	94.8	0.93							
Type of OCT																	
Conventional OCT	6 (1290)	93.4% (91.2 to 95.2)	59.0	86.7% (83.9 to 89.2)	90.5	6.93 (3.59 to 13.4)	90.6	0.08 (0.05 to 0.14)	58.5	0.97							
HD-OCT	6 (450)	87.9% (82.9 to 91.9)	73.8	86.8% (81.7 to 90.9)	79.6	7.65 (2.98 to 19.6)	80.8	0.18 (0.09 to 0.36)	72.7	0.94							
Design																	
Prospectively	6 (723)	90.6% (86.9 to 93.5)	77.4%	78.4% (74.0 to 82.4)	80.5	4.25 (2.85 to 6.33)	72.9	0.13 (0.06 to 0.30)	78.6	0.91							
Retrospectively	6 (999)	92.5% (90.0 to 94.6)	71.3%	93.5% (90.9 to 95.5)	29.5	12.08 (7.77 to 18.8)	27.8	0.10 (0.05 to 0.21)	78.9	0.97							
Experienced/NA																	
Experienced	7 (1396)	91.2% (88.8 to 93.2)	79.8	86.0% (83.3 to 88.5)	90.8	6.09 (3.18 to 11.6)	91.9	0.13 (0.07 to 0.25)	84.8	0.94							
NA	5 (344)	93.9% (89.6 to 96.8)	56.6	89.8% (83.7 to 94.2)	53.4	8.18 (4.38 to 15.3)	27.8	0.09 (0.03 to 0.26)	69.5	0.97							

Note: AUC, area under the curve; CI, confidence interval; BCC, basal cell carcinoma; SCC, squamous cell carcinoma; AK, actinic keratosis; MM, malignant melanoma; OCT, optical coherence tomography; HD-OCT, high-definition OCT; and NA, no data available.

68.01 (95% CI: 17.01 to 272.4, $I^2 = 0.0\%$) and 0.11 (95% CI: 0.01 to 1.20, $I^2 = 82.0\%$), respectively. The AUC for sROC was 1.00 (Table 3).

3.6 Diagnostic Accuracy of OCT for AK

Three studies^{44,46,48} addressed the diagnosis of AK with pooled sensitivity and specificity of 73.8% (95% CI: 0.67 to 0.80, $I^2 = 96.7\%$) and 91.5% (95% CI: 0.87 to 0.95, $I^2 = 0.0\%$), respectively. The pooled PLR and NLR were 7.67 (95% CI: 3.94 to 14.94, $I^2 = 40.4\%$) and 0.17 (95% CI: 0.02 to 1.34, $I^2 = 96.4\%$), respectively. The AUC for sROC was 0.97 (Table 3).

3.7 Diagnostic Accuracy of OCT for MM

Only two publications^{12,45} reported diagnoses of MM and achieved 81.0% (95% CI: 0.66 to 0.91, $I^2 = 62.3\%$), 93.8% (95% CI: 0.87 to 0.98, $I^2 = 0.0\%$), 11.82 (95% CI: 5.16 to 27.09, $I^2 = 3.4\%$), and 0.18 (95% CI: 0.05 to 0.71, $I^2 = 54.0\%$) for the pooled sensitivity, specificity, PLR, and NLR, respectively (Table 3).

3.8 Heterogeneity Analysis

Between-study heterogeneity of the 12 studies that reported diagnostic accuracy of OCT for skin cancers was explored using subgroup analyses classified by types of OCT (HD-OCT or conventional OCT), study design (prospective versus retrospective), and diagnosis mode (*in vivo* versus *ex vivo*).

Six studies used HD-OCT, such as Skintell HD-OCT^{12,40,44,45,48} and FF-OCT;⁴¹ the other six studies used conventional OCT, including VivoSight OCT^{1,39,42,46} and PS-OCT.^{13,47} The pooled sensitivity of HD-OCT was 87.9% (95% CI: 0.83 to 0.92, $I^2 = 73.8\%$), which was slightly lower than that of conventional OCT at 93.4% (95% CI: 0.92 to 0.95, $I^2 = 59.0\%$). However, the pooled specificity of HD-OCT was similar to that of conventional OCT [86.8% (95% CI: 0.82 to 0.91, $I^2 = 79.6\%$) versus 86.7% (95% CI: 0.84 to 0.89, $I^2 = 90.5\%$)] (Table 3).

Moreover, the pooled sensitivity of nine studies with *in vivo*^{1,12,13,39,42,44-46,48} and three with *ex vivo*^{40,41,47} imaging was 91.6% (95% CI: 0.89 to 0.94, $I^2 = 62.3\%$) and 92.1% (95% CI: 0.89 to 0.95, $I^2 = 89.6\%$); and their pooled specificity was 84.1% (95% CI: 0.81 to 0.87, $I^2 = 76.4\%$) and 91.1% (95% CI: 0.87 to 0.94, $I^2 = 93.9\%$), respectively (Table 3).

We also conducted a meta-regression to explore potential heterogeneity. In the meta-regression, we included six variables: (i) diagnosis mode (*in vivo* versus *ex vivo*), (ii) number of lesions (≥ 50 versus < 50), (iii) study center (single versus multiple), (iv) type of cancer, (v) observer's experience (experienced versus nonexperienced), and (vi) type of OCT (HD-OCT versus conventional OCT). The meta-regression analysis failed to reveal any factor that contributed to the heterogeneity.

3.9 Publication Bias

The funnel plots for publication bias were symmetrical, and Deek's test indicated no statistically significant publication bias ($p = 0.19$).

4 Discussion

Dermoscopy is a widely used method for the clinical diagnosis of skin diseases.¹² A meta-analysis reported the diagnostic accuracy of dermoscopy has a sensitivity of 83.2% and specificity of 85.8%,⁵¹ which were both superior to the diagnostic accuracy achieved with the unaided eye. Among high-resolution optical imaging technologies, reflectance confocal microscopy (RCM) is reported to be one of the best techniques for noninvasive diagnosis.¹² Previous reports have demonstrated that RCM has a sensitivity of 94% and specificity of 83% for skin cancer diagnoses.^{12,52} However, as one of the most time-consuming and costly diagnostic methods, RCM can be difficult to apply in daily practice.^{12,52} OCT is an alternative method with the advantage of avoiding pre- and posttreatment biopsies. Moreover, functional quantitative information can be extracted (that is, flow information, layer thickness, and attenuation coefficient of the OCT signal).^{53,54} To the best of our knowledge, this is the first meta-analysis on the accuracy of OCT technique in diagnosing skin tumors. We assessed the accuracy of OCT in detecting dermatologic lesions as reported in 14 studies involving more than 813 patients and 1958 lesions. Our results indicate that OCT can accurately differentiate cancerous from noncancerous lesions with a pooled sensitivity of 91.8% (95% CI: 0.90 to 0.94) and specificity of 86.7% (95% CI: 0.84 to 0.89), values that are higher than those of dermoscopy,⁵¹ and approximately equal to those of RCM.^{12,52}

BCC is one of the most common skin cancers, with a prevalence exceeding all other skin cancers combined. Most clinical studies of OCT are focused on diagnostic accuracy for BCC, and they report a sensitivity of 79% to 94% and specificity of 85% to 96%.¹³ From our analysis, the pooled sensitivity and specificity of OCT for BCC were 92.4% (95% CI: 0.90 to 0.94) and 86.9% (95% CI: 0.87 to 0.89), respectively. Additionally, we assessed the diagnostic accuracy of OCT for SCC, AK, and MM, with a pooled sensitivity of 92.3% (95% CI: 0.79 to 0.99), 73.8% (95% CI: 0.67 to 0.80), and 81.0% (95% CI: 0.66 to 0.92), respectively. Similarly, the specificities for the diagnoses were 99.5% (95% CI: 0.97 to 1.00) for SCC, 91.5% (95% CI: 0.87 to 0.96) for AK, and 93.8% (95% CI: 0.87 to 0.98) for MM.

Several studies reported that the main limitation of OCT for diagnosing BCC is an inability to identify its subtypes.^{13,16} This may suggest that the diagnostic features of BCC are too subtle to recognize in the OCT images.⁴⁶ Cheng et al.⁴⁹ reported that the sensitivity and specificity of OCT for superficial BCC were 87.0% and 80.0%, respectively, which indicated that the improvements of the OCT technique now allow detailed imaging of structures within the uppermost layers of the skin, and have made it possible to identify the morphology of the different subtypes of BCC in the clinic.^{55,56} Newer studies are focusing on determining diagnostic accuracy based on scoring systems⁴³ or algorithms^{47,48} as adjunctive tools in the clinical setting. Wahrlich et al.⁴³ validated diagnostic BCC using OCT with a newly developed scoring system (BS). Their study found that application of the OCT by students revealed a sensitivity and specificity of 92.8% and 24.1%, respectively. However, the sensitivity and specificity amounted to 96.6% and 75.2% when the OCT used by dermatological specialists and experts, showing that experience markedly increased the sensitivity and specificity of the diagnosis of BCC.

The thickness of BCC is an important prognostic factor. A study of 127 BCC patients treated with imiquimod showed a recurrence rate of 58% in lesion thickness > 0.40 mm, whereas

there was no recurrence in lesion thickness ≤ 0.4 mm (mean follow-up period 34 months).⁵⁷ However, it is difficult to accurately determine the thickness of BCC tumors using clinical examination alone.⁵⁸ OCT provides a useful tool for depth measurement of BCC thickness, particularly for thin tumors < 0.4 mm. Cheng et al.⁴⁹ reported that there was excellent correlation between OCT and biopsy for tumor depth among ≤ 0.4 mm (Pearson's correlation $r = 0.86$, $p < 0.001$), but the correlation was becoming smaller with increase of the depth of thickness. Therefore, the use of OCT can guide an appropriate treatment for BCC based on tumor thickness.

The conventional OCT system has a penetration depth of up to 2 mm, with an optical lateral resolution of at least $7.5 \mu\text{m}$ and axial resolution of at least $5 \mu\text{m}$.⁴² The HD-OCT devices possess a scan area of 1.8×0.5 mm and a penetration depth of 450 to $750 \mu\text{m}$ in optimal conditions.⁴⁰ Although HD-OCT has a lower penetration depth than conventional OCT, it provides imaging with a higher lateral and axial resolution of about $3 \mu\text{m}$, making it possible to visualize specific 3-D image details in either mode (i.e., *en-face* visualization in slice mode and vice versa) with real-time scanning.^{40,59} Nonetheless, it seems that the diagnostic limitations of HD-OCT are such that it cannot reliably rule out melanoma based on a morphology analysis.¹² Our subgroup analysis found that HD-OCT has a sensitivity of 87.9%, which was lower than that of conventional OCT (93.4%), whereas the specificity of HD-OCT was similar to conventional OCT (86.8 versus 86.7%).

There is a limited penetration depth for *in vivo* examination (< 1 mm),^{60,61} which does not allow a complete evaluation of the tumor depth, whereas in *ex vivo* imaging, the scanning process is not limited to a certain depth.⁴⁰ In a recent study, OCT was applied *ex vivo* in the detection of BCC on frozen sections prepared for Mohs micrographic surgery and resulted in a low specificity (56%) and low sensitivity (19%).⁶² This result derived mainly from the reduced contrast in OCT images that have previously been noted in *ex vivo* samples and possibly as a result of increased optical scatter in nonperfused tissue.⁶² Our study shows that the sensitivity of *ex vivo* and *in vivo* detection was 92.1% and 91.6%, and the specificity was 91.1% and 84.1%, respectively. The field of *ex vivo* imaging is rapidly evolving, and perhaps the next generation of devices will capture sufficient nuclear detail.⁴¹

Use of noninvasive techniques for determining the depth of BCC thickness would obviate the need for invasive tissue biopsy. Cheng et al.⁴⁹ reported that there was a potential 76% reduction of biopsy with a 5% error rate using OCT. Ulrich et al.⁴² found that the diagnostic accuracy of BCC increased from 65.8% (clinical) to 76.2% (clinical + dermoscopy) to 87.4% (clinical + dermoscopy + OCT). Markowitz et al.³⁹ also found that the overall diagnostic accuracy was 57% with clinical examination alone; however, the rate rose to 70% with dermoscopy and 88% with OCT, and the results showed that more than 1 in 3 patients would avoid diagnostic biopsy in combination of these three methods by the improved specificity.

As previous studies have reported, OCT has several primary benefits for clinical practice. First, OCT can increase the diagnoses of cancerous lesions and reduce the incidence of false-negative examinations.³⁹ Second, by identifying lesions earlier, treatment measures can be initiated in a timely manner, with improved clinical and cosmetic outcomes and reduced morbidity.^{39,42} Third, OCT could provide information on

tumor margins and depth, so that surgical interventions can be planned better.^{63,64} Fourth, OCT may complement other imaging methods, such as RCM or dermoscopy. Fifth, OCT could monitor the progress of noninvasive treatment. Sixth, OCT could reduce biopsy. OCT with sophisticated lasers has not yet achieved cellular resolution images,⁶⁵ although its imaging characteristics indicate that this should be possible. In one study to assess OCT imaging in the diagnosis of NMSC, 59% of the lesions were discarded,¹³ mainly as a result of artifacts caused by too little gel, hyperkeratosis, motion, and mismatch of the probe and skin.^{15,62} These findings suggest that refining OCT diagnostic criteria and improving image quality and resolution can increase diagnostic accuracy.^{13,66}

We reported results of diagnostic accuracy of OCT for skin tumors in the meta-analysis, including the limitations and potential biases. The sources of bias include variation in (i) study design, (ii) inclusion and exclusion criteria, (iii) type of OCT device, and (iv) the clinical experience of the observer. One study¹² met our inclusion criteria but was excluded because the images obtained in more than half of the cases were inadequate. All of the aforementioned contribute to heterogeneity. Although we used a random-effects model, between-study variation was taken into account, and there was still some influence on the results. In addition, not all the studies were of high quality, which might lead to some bias in the final statistical results.

5 Conclusions

OCT appears to have significant potential for improving diagnosis of BCC and SCC, and for monitoring and therapy of skin cancers. Combinations of OCT with other imaging techniques, such as RCM, refining the OCT morphological diagnostic criteria, as well as improving image quality and resolution of OCT images could improve our capability to easily and accurately diagnose many skin cancers.

Disclosures

No conflicts of interest, financial or otherwise, are declared by the authors.

Compliance with Ethical Standards

This article does not contain any studies with human participants performed by any of the authors.

References

1. A. A. Hussain et al., "Adjunct use of optical coherence tomography increases the detection of recurrent basal cell carcinoma over clinical and dermoscopic examination alone," *Photodiagn. Photodyn. Ther.* **14**, 178–184 (2016).
2. F. Birch-Johansen et al., "Trends in the incidence of nonmelanoma skin cancer in Denmark 1978–2007: rapid incidence increase among young Danish women," *Int. J. Cancer* **127**, 2190–2198 (2010).
3. E. de Vries and J. W. Coebergh, "Cutaneous malignant melanoma in Europe," *Eur. J. Cancer* **40**, 2355–2366 (2004).
4. M. Trakatelli et al., "Epidemiology of nonmelanoma skin cancer (NMSC) in Europe: accurate and comparable data are needed for effective public health monitoring and interventions," *Br. J. Dermatol.* **156**(Suppl. 3), 1–7 (2007).
5. D. Wielowieyska-Szybinska et al., "The use of reflectance confocal microscopy for examination of benign and malignant skin tumors," *Adv. Dermatol. Allergol.* **31**, 380–387 (2014).
6. C. A. Banzhaf et al., "Optical coherence tomography imaging of non-melanoma skin cancer undergoing imiquimod therapy," *Skin Res. Technol.* **20**, 170–176 (2014).

7. M. Mogensen and G. B. Jemec, "Diagnosis of nonmelanoma skin cancer/keratinocyte carcinoma: a review of diagnostic accuracy of non-melanoma skin cancer diagnostic tests and technologies," *Dermatol. Surg.* **33**, 1158–1174 (2007).
8. World Health Organization, "Skin cancers. How common is skin cancer," <http://www.who.int/uv/faq/skincancer/en/index1.html> (2016).
9. A. Lomas, J. Leonardi-Bee, and F. Bath-Hextall, "A systematic review of worldwide incidence of nonmelanoma skin cancer," *Br. J. Dermatol.* **166**, 1069–1080 (2012).
10. A. M. Forsea et al., "Melanoma incidence and mortality in Europe: new estimates, persistent disparities," *Br. J. Dermatol.* **167**, 1124–1130 (2012).
11. C. M. Balch et al., "Final version of 2009 AJCC melanoma staging and classification," *J. Clin. Oncol.* **27**, 6199–6206 (2009).
12. T. Gambichler et al., "A multicentre pilot study investigating high-definition optical coherence tomography in the differentiation of cutaneous melanoma and melanocytic naevi," *J. Eur. Acad. Dermatol. Venereol.* **29**, 537–541 (2015).
13. M. Mogensen et al., "Assessment of optical coherence tomography imaging in the diagnosis of non-melanoma skin cancer and benign lesions versus normal skin: observer-blinded evaluation by dermatologists and pathologists," *Dermatol. Surg.* **35**, 965–972 (2009).
14. C. Reggiani et al., "Update on non-invasive imaging techniques in early diagnosis of non-melanoma skin cancer," *G. Ital. Dermatol. Venereol.* **150**, 393–405 (2015).
15. C. Wassef and B. K. Rao, "Uses of non-invasive imaging in the diagnosis of skin cancer: an overview of the currently available modalities," *Int. J. Dermatol.* **52**, 1481–1489 (2013).
16. M. A. Calin et al., "Optical techniques for the noninvasive diagnosis of skin cancer," *J. Cancer Res. Clin. Oncol.* **139**, 1083–1104 (2013).
17. T. Gambichler et al., "Applications of optical coherence tomography in dermatology," *J. Dermatol. Sci.* **40**, 85–94 (2005).
18. S. Q. Wang et al., "Current technologies for the in vivo diagnosis of cutaneous melanomas," *Clin. Dermatol.* **22**, 217–222 (2004).
19. N. Kollias and G. N. Stamatias, "Optical non-invasive approaches to diagnosis of skin diseases," *J. Invest. Dermatol. Symp. Proc.* **7**, 64–75 (2002).
20. A. F. Fercher, K. Mengedocht, and W. Werner, "Eye-length measurement by interferometry with partially coherent light," *Opt. Lett.* **13**, 186–188 (1988).
21. H. M. Cheng and P. Guitera, "Systematic review of optical coherence tomography usage in the diagnosis and management of basal cell carcinoma," *Br. J. Dermatol.* **173**, 1371–1380 (2015).
22. J. Welzel, "Optical coherence tomography in dermatology: a review," *Skin Res. Technol.* **7**, 1–9 (2001).
23. A. Knüttel and M. Boehlau-Godau, "Spatially confined and temporally resolved refractive index and scattering evaluation in human skin performed with optical coherence tomography," *J. Biomed. Opt.* **5**, 83–92 (2000).
24. T. Hinz et al., "Assessment of tumor thickness in melanocytic skin lesions: comparison of optical coherence tomography, 20-MHz ultrasound and histopathology," *Dermatology* **223**, 161–168 (2011).
25. T. Gambichler et al., "In vivo optical coherence tomography of basal cell carcinoma," *J. Dermatol. Sci.* **45**, 167–173 (2007).
26. C. Salvini et al., "Application of optical coherence tomography in non-invasive characterization of skin vascular lesions," *Skin Res. Technol.* **14**, 89–92 (2008).
27. M. Boone et al., "High-definition optical coherence tomography enables visualization of individual cells in healthy skin: comparison to reflectance confocal microscopy," *Exp. Dermatol.* **21**, 740–744 (2012).
28. T. M. Jorgensen et al., "Machine-learning classification of non-melanoma skin cancers from image features obtained by optical coherence tomography," *Skin Res. Technol.* **14**, 364–369 (2008).
29. T. Gambichler et al., "Characterization of benign and malignant melanocytic skin lesions using optical coherence tomography in vivo," *J. Am. Acad. Dermatol.* **57**, 629–637 (2007).
30. M. Mogensen et al., "How histological features of basal cell carcinomas influence image quality in optical coherence tomography," *J. Biophotonics* **4**, 544–551 (2011).
31. A. M. Forsea et al., "Clinical application of optical coherence tomography for the imaging of non-melanocytic cutaneous tumors: a pilot multi-modal study," *J. Med. Life* **3**, 381–389 (2010).
32. M. A. Boone et al., "Imaging actinic keratosis by high-definition optical coherence tomography. Histomorphologic correlation: a pilot study," *Exp. Dermatol.* **22**, 93–97 (2013).
33. D. Moher et al., "Preferred reporting items for systematic reviews and meta-analyses: the PRISMA statement," *PLoS Med.* **6**, e1000097 (2009).
34. J. Howick et al., "Oxford centre for evidence-based medicine-levels of evidence," <http://www.cebm.net/oxford-centre-evidence-based-medicine-levels-evidence-march-2009/> (2009).
35. P. F. Whiting et al., "QUADAS-2: a revised tool for the quality assessment of diagnostic accuracy studies," *Ann. Intern. Med.* **155**, 529–536 (2011).
36. L. E. Moses, D. Shapiro, and B. Littenberg, "Combining independent studies of a diagnostic test into a summary ROC curve: data-analytic approaches and some additional considerations," *Stat. Med.* **12**, 1293–1316 (1993).
37. R. DerSimonian and N. Laird, "Meta-analysis in clinical trials," *Controlled Clin. Trials* **7**, 177–188 (1986).
38. J. Zamora et al., "Meta-DiSc: a software for meta-analysis of test accuracy data," *BMC Med. Res. Method.* **6**, 31 (2006).
39. O. Markowitz et al., "Evaluation of optical coherence tomography as a means of identifying earlier stage basal cell carcinomas while reducing the use of diagnostic biopsy," *J. Clin. Aesthetic Dermatol.* **8**, 14–20 (2015).
40. T. Maier et al., "Ex vivo high-definition optical coherence tomography of basal cell carcinoma compared to frozen-section histology in micrographic surgery: a pilot study," *J. Eur. Acad. Dermatol. Venereol.* **28**, 80–85 (2014).
41. J. R. Durkin et al., "Imaging of Mohs micrographic surgery sections using full-field optical coherence tomography: a pilot study," *Dermatol. Surg.* **40**, 266–274 (2014).
42. M. Ulrich et al., "The sensitivity and specificity of optical coherence tomography for the assisted diagnosis of nonpigmented basal cell carcinoma: an observational study," *Br. J. Dermatol.* **173**, 428–435 (2015).
43. C. Wahrlich et al., "Assessment of a scoring system for basal cell carcinoma with multi-beam optical coherence tomography," *J. Eur. Acad. Dermatol. Venereol.* **29**, 1562–1569 (2015).
44. A. Marneffe et al., "Validation of a diagnostic algorithm for the discrimination of actinic keratosis from normal skin and squamous cell carcinoma by means of high-definition optical coherence tomography," *Exp. Dermatol.* **25**(9), 684–687 (2016).
45. M. A. L. M. Boone et al., "In vivo assessment of optical properties of melanocytic skin lesions and differentiation of melanoma from non-malignant lesions by high-definition optical coherence tomography," *Arch. Dermatol. Res.* **308**(1), 7–20 (2016).
46. J. Olsen et al., "Diagnostic accuracy of optical coherence tomography in actinic keratosis and basal cell carcinoma," *Photodiagn. Photodyn. Ther.* **16**, 44–49 (2016).
47. T. Marvdashti et al., "Classification of basal cell carcinoma in human skin using machine learning and quantitative features captured by polarization sensitive optical coherence tomography," *Biomed. Opt. Express* **7**(9), 3721–3735 (2016).
48. M. A. L. M. Boone et al., "A new algorithm for the discrimination of actinic keratosis from normal skin and squamous cell carcinoma based on in vivo analysis of optical properties by high-definition optical coherence tomography," *Acad. Dermatol. Venereol.* **30**(10), 1714–1725 (2016).
49. H. M. Cheng et al., "Accuracy of optical coherence tomography for the diagnosis of superficial basal cell carcinoma: a prospective, consecutive, cohort study of 168 cases," *Br. J. Dermatol.* **175**, 1290–1300 (2016).
50. A. A. Hussain, L. Themstrup, and G. B. Jemec, "Optical coherence tomography in the diagnosis of basal cell carcinoma," *Arch. Dermatol. Res.* **307**, 1–10 (2015).
51. H. Kittler et al., "Diagnostic accuracy of dermoscopy," *Lancet Oncol.* **3**, 159–165 (2002).
52. Y. D. Xiong et al., "A meta-analysis of reflectance confocal microscopy for the diagnosis of malignant skin tumours," *J. Eur. Acad. Dermatol. Venereol.* **30**, 1295–1302 (2016).
53. E. J. van Zeeburg et al., "Early perfusion of a free RPE-choroid graft in patients with exudative macular degeneration can be imaged with spectral domain-OCT," *Invest. Ophthalmol. Visual Sci.* **52**, 5881–5886 (2011).

54. V. J. Srinivasan et al., "OCT methods for capillary velocimetry," *Biomed. Opt. Express* **3**, 612–629 (2012).
55. T. Maier et al., "Morphology of basal cell carcinoma in high definition optical coherence tomography: en-face and slice imaging mode, and comparison with histology," *J. Eur. Acad. Dermatol. Venereol.* **27**, e97–e104 (2013).
56. M. A. Boone et al., "Imaging of basal cell carcinoma by high-definition optical coherence tomography: histomorphological correlation. A pilot study," *Br. J. Dermatol.* **167**, 856–864 (2012).
57. K. M. McKay et al., "Thickness of superficial basal cell carcinoma (sBCC) predicts imiquimod efficacy: a proposal for a thickness-based definition of sBCC," *Br. J. Dermatol.* **169**, 549–554 (2013).
58. E. Christensen et al., "Comparison of clinical and histopathological evaluations of basal cell carcinoma thickness," *Br. J. Dermatol.* **173**, 578–580 (2015).
59. M. A. Boone et al., "High-definition optical coherence tomography imaging of melanocytic lesions: a pilot study," *Arch. Dermatol. Res.* **306**, 11–26 (2014).
60. A. Kardynal and M. Olszewska, "Modern non-invasive diagnostic techniques in the detection of early cutaneous melanoma," *J. Dermatol. Case Rep.* **8**, 1–8 (2014).
61. T. Hinz et al., "Preoperative characterization of basal cell carcinoma comparing tumour thickness measurement by optical coherence tomography, 20-MHz ultrasound and histopathology," *Acta Derm.-Venerol.* **92**, 132–137 (2012).
62. D. Cunha et al., "Comparison of ex vivo optical coherence tomography with conventional frozen-section histology for visualizing basal cell carcinoma during Mohs micrographic surgery," *Br. J. Dermatol.* **165**, 576–580 (2011).
63. S. A. Alawi et al., "Optical coherence tomography for presurgical margin assessment of non-melanoma skin cancer—a practical approach," *Exp. Dermatol.* **22**, 547–551 (2013).
64. K. X. Wang et al., "Optical coherence tomography-based optimization of Mohs micrographic surgery of Basal cell carcinoma: a pilot study," *Dermatol. Surg.* **39**, 627–633 (2013).
65. F. Spoler et al., "High-resolution optical coherence tomography as a non-destructive monitoring tool for the engineering of skin equivalents," *Skin Res. Technol.* **12**, 261–267 (2006).
66. G. Isenberg et al., "Accuracy of endoscopic optical coherence tomography in the detection of dysplasia in Barrett's esophagus: a prospective, double-blinded study," *Gastrointest. Endoscopy* **62**, 825–831 (2005).

Yi-Quan Xiong is a doctoral candidate at the Southern Medical University, who majored in clinical epidemiology and evidence-based medicine. He has published several system reviews focusing on the application of optical imaging technology in tumor diagnosis.

Biographies for the other authors are not available.